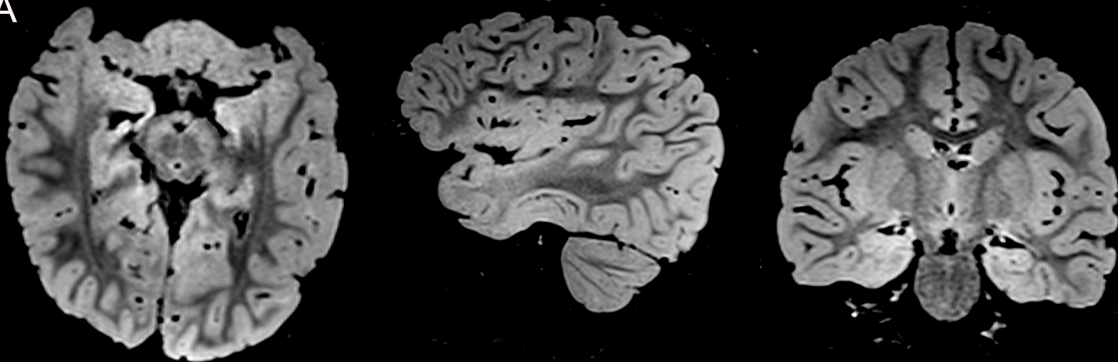
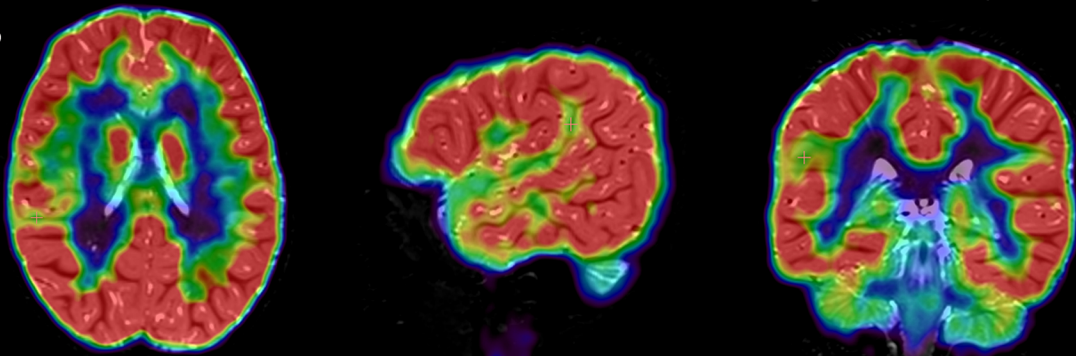


A



B



Supplementary Figure S1: Fluid-attenuated inversion recovery (FLAIR) MRI (A) and PET-CT (B) images of the patient's brain, showing no visible lesions. However, FDG PET-CT scan (B) shows focal areas of hypometabolism in the opercular area