

Supplementary Table 1- Searching strategy in electronic databases including updated searching

Number	Key words
1	Bovine pericardium
2	Bladder
3	Urethra
4	Ureter
5	Pelvis
6	Kidney
7	Penis
8	1 OR 2 OR 3 OR 4 OR 5 OR 6 OR 7
9	Pericardium OR 2 OR 3 OR 4 OR 5 OR 6 OR 7
10	9 and 8

Publication date from 1950

Supplementary Table 2- Details of outcomes in studies using the pericardial tissue in the humans

Author	Year	Detailed outcomes
Leungwattanakij	2001	<p>All patients had successful sexual intercourse after follow-up.</p> <p>No patient reported penile shortening.</p> <p>Nine of eleven cases had straight penis, 1 had 10-degree curvature and in 1 patient curvature progressed from 10 to 30 degrees at 18-month follow-up.</p> <p>Two complications included left urethrocorporal communication on retrograde urethrography 3 weeks later and a slight bulge over the excised plaque area.</p> <p>At mean of 30 months follow-up, five patients did well initially, but later reported difficulty maintaining erection due to venous leakage and needed a vacuum constriction device or ring.</p>
Chun	2001	<p>Twenty-two patients (92%) reported successful coitus after surgery.</p> <p>One patient with a dermal graft did not respond to adjuvant therapy and required a penile prosthesis, while 15 of the 24 (63%) needed assistance to achieve erection rigid enough for satisfactory coitus, including sildenafil in 10, a vacuum erection device in 3, intracorporeal injection in 1, and an inflatable penile prosthesis in 1.</p> <p>Curvature recurred in 4 patients each with a dermal (26.7%) and pericardial graft (44.4%).</p> <p>Two patients with a dermal graft (13.3%) reported decreased sensation of glans.</p>
Palese	2001	<p>Two patients (50%) were without complications.</p> <p>One patient (25%) had prosthesis erosion and it was explanted. Another patient (25%) had prosthesis malfunction which led to scrotal abscess.</p>
Egydio	2002	<p>No infection, retraction, or rejection of the graft occurred.</p> <p>One patient who complained of hypoesthesia recovered in the second month.</p> <p>Complete penile straightening in 29 (87.9%) and curvature of less than 15° in 4 (12.1%).</p> <p>All the patients maintained erection and ability to penetrate and had re-established satisfactory sexual activity</p>
Gulino	2002	<p>Tutoplast seems to be reliable graft due to its preserved elasticity at long-term follow-up.</p> <p>Porcine intestine submucosa has shown best remodeling, low rate of complications, and good clinical results.</p> <p>Vein has shown the best biocompatibility and elasticity at medium and long-term follow-up; however, it requires second operation to isolate vein itself.</p> <p>Gor-Tex showed high rate of complications and infection.</p> <p>Alloderm showed good elasticity and long-term clinical results.</p> <p>In spite of good experience with alloderm, HCP and porcine intestine submucosa had better remodeling.</p>
Pais	2002	<p>A subcutaneous nodule was noted on the right side of the penile shaft which remained unchanged at 6 months.</p> <p>Pathological evaluation revealed xanthogranulomatous reaction, including foamy macrophages, chronic inflammation and foreign body giant cells.</p> <p>After mass excised, the defect in the tunica albuginea was patched with an autologous dermal graft with good outcome.</p>
Pelosi	2002	<p>Seventeen patients (77.3%) had no notation of incontinence. Four patients (18.2%) had a 90% or greater decrease in incontinence notations.</p> <p>All but one patient assessed herself as cured.</p> <p>There was no evidence of local or systemic reaction to the BP patch in any of the patients. There were no complications.</p>
Usta	2003	<p>Forty-six patients (83.6%) and 40 partners (76.9%) stated high satisfaction.</p> <p>Five patients (with residual curvature >30°, one with an explanted prosthesis, and two with complaints of penile shortening were not satisfied with the surgical results.</p> <p>The hypoesthesia of glans developed in 10% of patients.</p> <p>Two patients undergoing plaque excision plus HCP graft reported little benefit from the</p>

		surgery.
Thiel	2005	Three months postoperatively had a large painless subcutaneous nodule over the location of the previously placed HCP graft. The nodule failed to resolve over a 6-month period following a regimen of hot soaks and penile stretching. The patient also noted a gradual return of penile curvature to greater than preoperative status. The area of the previously placed graft was occupied by a 2cm mass. Pathologic examination of the specimen revealed an inclusion cyst with severe surrounding histiocytic reaction. The mass was excised and the tunical defect patched with an autologous temporalis fascia graft
Lopes	2007	Two years later, the patient is satisfied with the result and has been maintaining regular sexual relations without any complaints or recurrences.
Taylor	2008	Penile curvature of less than 30° was reported in 91% of patients. Objective flaccid stretched penile length measurements showed an average length gain of 0.2 cm (range -1.5 to 2.0 cm). Sensation was reported as good as or better than preoperative in 69%; however, 90% were capable of achieving orgasm. Postoperative erectile dysfunction was reported in 91% of patients. Surgical outcome was reported as either very satisfied or satisfied in 75% of patients. No patient underwent repeated graft insertion; however, two patients (2.5%) were required penile prosthesis implant for postoperative erectile dysfunction.
Egydio	2008	No infections occurred. Sexual intercourse was restored in all patients. All patients reported recovered self-esteem.
Lopes	2009	All patients were satisfied and no complications were observed at mean of 32 months follow-up.
Gunasekaran	2011	There were no complications.
Moon	2011	Cystography in postoperative week 8 showed no dye leakage associated with vesicoureteral reflux and contracted bladder. Cystoscopy at six months showed intact substituted pericardium at the bladder dome.
Chung	2011	Only 46 patients (53%) were able to be contacted and consented for telephone interview. At the 6 weeks postoperative follow-up, 60% of dermal, 100% of Tutoplast, and 86% of Stratis patients achieved self-described resolution, or significantly less, penile curvature. Only 50% of dermal, 87% of Tutoplast, and 76% of Stratis patients reported minimal recurrence of penile curvature. Altered penile sensation and glans hypoesthesia were reported in 13% and 4% of patients. Penile rigidity (IIEF-5 Questions 3 and 4) was found to be significantly lowered when compared with preoperative IIEF-5 scores ($P < 0.01$). Sexual desire and intercourse satisfaction domains were unchanged in most patients ($P > 0.05$). A total of five patients (5.8%) underwent penile prosthesis implantation. 65% of all patients dissatisfied with the outcomes of the Peyronie's graft surgery.
Flores	2011	Stretched flaccid penile length increased 0.4 cm, but it was not significant. Forty-six percent of men experienced a 6-point decrease in erectile function (measured by international index of erectile dysfunction) domain score after grafting. (16%) patients complained of some distal penile sensory loss within 1 month of the operation; however, at 6 months, all had full subjective recovery
Sansalone	2011	No rejection of the graft was observed. All patients recovered their ability to penetrate with no difficulty. Mild residual curvature (12%) and mild glans hypoesthesia (3%) were the only causes of partial dissatisfaction.
Uhlman	2012	BP results in low amounts of scarring in the operating region, very little infarct on follow-up imaging evaluation, and is easier to manipulate during preparation and while operating

Zucchi	2013	<p>Erection was completely preserved in 24 patients. The remaining 36 patients had mild to moderate erectile dysfunction; six of them were diabetics.</p> <p>100% resumed sexual activity within 4 months.</p> <p>All patients reported a loss of sensitivity on the glans and 48 (80%) of them regained sensitivity after 8 months.</p> <p>The mean IIEF score was 15.5 before surgery, improving after surgery 23 at 24 months.</p> <p>Over 80% of couples reported good results in terms of recovery of natural sexual intercourse and of original length and girth of the penis.</p> <p>17% of patients reported persistent sensation of a cold gland and low sensitivity of the penis after 1 year.</p> <p>Fifteen patients (25%) reported regular sexual intercourse with more than one partner and 15% reported that they had a stable relationship with a new partner.</p> <p>One patient had erosion of the tip of the corpora cavernosa after 7 months, one patient had prosthesis extrusion</p> <p>6 months after implantation, and two patients had hematoma of the dartos.</p>
Egydio	2013	<p>The overall patient satisfaction rate was 89.4%.</p> <p>Three patients (2.9%) developed retraction with residual curvature of up to 30 °, but no re-operation was necessary.</p> <p>In one (1%) patient, the prosthesis had to be removed because of wound infection.</p> <p>104 patients (99%) were able to have sexual intercourse.</p>
Ciftci	2014	<p>At postoperative 3 months, Doppler sonography demonstrated a good arterial blood flow, and magnetic resonance imaging revealed normal integrity and volume of the right testis.</p>
Segal	2014	<p>There were no specified results based on patients undergoing pericardial graft implantation, and all outcomes were reported for a group of patients undergoing penile reconstruction using Gore-tex, allograft dermis, and pericardial graft.</p>
Chee	2015	<p>Cystography at 1 month showed no leakage around the patch. Flexible cystoscopy showed the bovine pericardium integrated into the native tissue.</p> <p>At 15 months postoperatively, normal kidney function was observed</p>
Otero	2016	<p>Two patients missed at follow-up.</p> <p>Complete penile straightening was achieved in 33 patients (80.5%), and 5 (12.2%) had curvature less than 20 degrees.</p> <p>35 patients (85.4%) reported satisfaction with treatment.</p> <p>Seventy-five percentage of patients reported being able to achieve successful intercourse without further treatment.</p> <p>There were no evidences of tissue rejection or infection and patch retraction.</p> <p>4 patients (9.7%) suffered an adverse event, including 1 ischemia of the glans, 1 penile edema, and 2 loss of sensation.</p>
Silva-Garretón	2016	<p>Curve correction was achieved in 26 patients (95.3%).</p> <p>Twenty-one patients (75%) expressed satisfaction with surgery.</p> <p>Correction of the curve suitable for a satisfactory sexual relationship in 96.3% of patients.</p> <p>One patient (3.57%) required residual curve correction using Yachia's technique. He had prosthetic infection and urethrocutaneous fistulae leading to 2-time urethroplasty.</p> <p>Twelve patients (44.4%) reported some degrees of erectile dysfunction requiring treatment.</p>

DVT, deep vein thrombosis; HCP, human cadaveric pericardium; IIEF, international index of erectile dysfunction; IVC, inferior vena cava; RCC, renal cell carcinoma

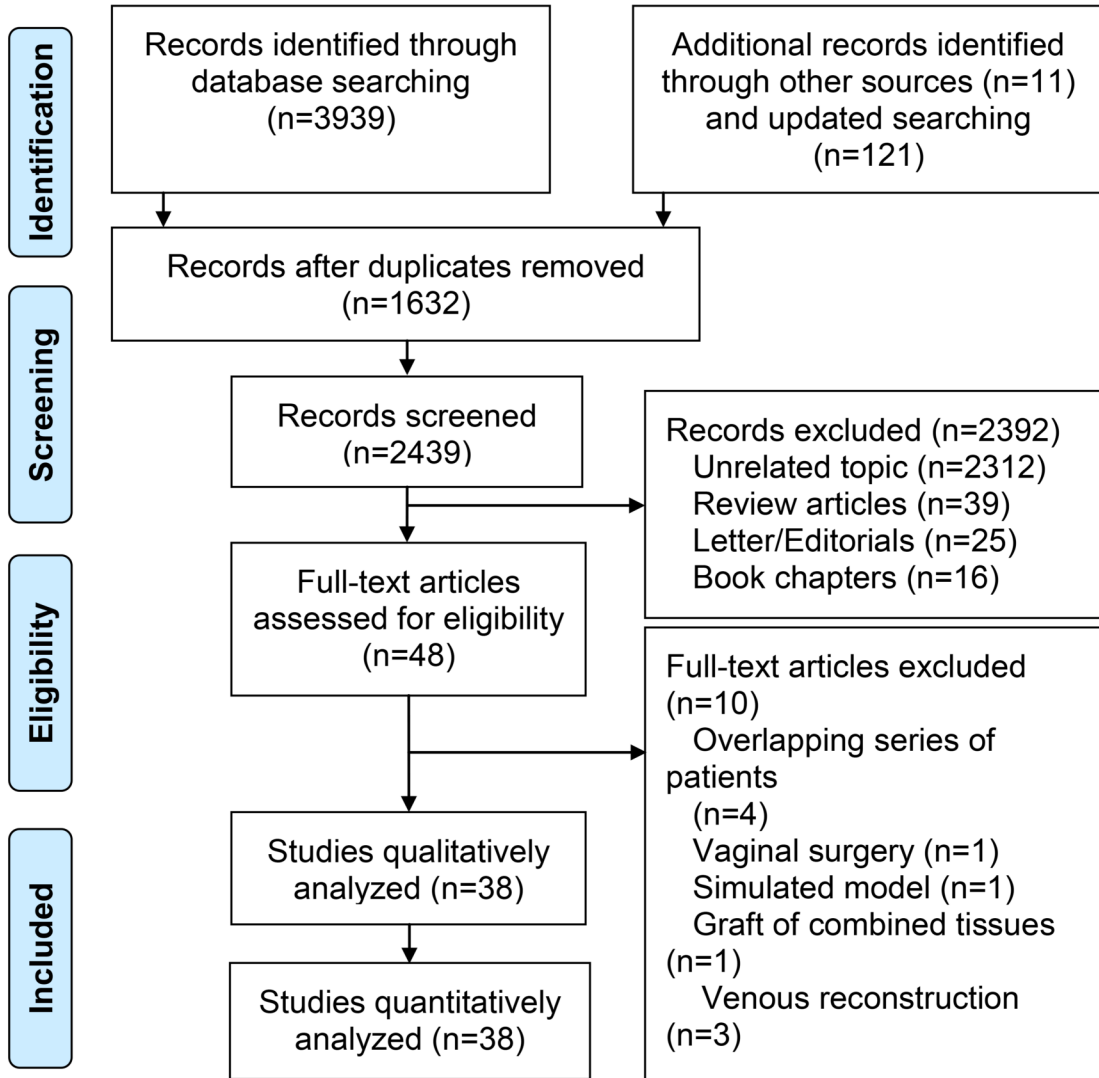
Supplementary Table 3- Details of outcomes in studies using the pericardial tissue in the animal models

Author	Published year	Detailed outcomes
Nakazono	1973	<p>One dog (20%) sacrificed at 1 week had urine leakage; however, a rather tight adhesion of the omentum to the implanted membrane was observed.</p> <p>In the other four dogs, no infection, leakage, fistula, nor stone formation were observed.</p> <p>In tow dogs sacrificed at 4 and 6 weeks, there was an adhesion of ileum and omentum to the regenerated bladder tissue. The implanted BP could not be found.</p> <p>Two dogs were followed up for 14 and 18 weeks. Biopsy showed regenerated and original bladder tissue. Cystoscopic studies showed normal physiologic bladder.</p> <p>Treated BP resolved within 4 weeks and completely replaced by regenerated transitional epithelium. By 18 weeks, the bladder wall regenerated with smooth muscle and exhibited normal function</p>
Novick	1978	<p>There were no cases of urinary extravasation following bladder surgery, and none of the animals developed bladder calculi postoperatively.</p> <p>After 1 year, bladders had complete regeneration of transitional epithelium with no evidence of residual pericardial graft on microscopic examination in all animals.</p> <p>A solitary micro focus of bone lying beneath intact epithelium and one animal with mild lymphangiectasis confined to the deep muscularis were seen in one animal with BP graft covered by omentum graft who sacrificed 1 year later.</p> <p>In animals with continuous biopsies, fourteen weeks later, the bladder appeared completely normal grossly, and no pericardial graft remained. 10 weeks later, biopsies revealed a solitary micro focus of bone within the depths of the bladder wall adjacent to the residual graft.</p> <p>In animals with contracted bladder, gross and microscopic pathologic studies 6 months after grafting revealed foci of pyelonephritis in the kidneys of all four animals. Microscopic examination of the bladders revealed intact transitional epithelium in all cases. Neither residual pericardium nor metaplastic bone formation was seen in any animal.</p> <p>The biodegradable graft was equally successful when applied either to a histologically normal bladder remnant, or to a pathological bladder of intramural fibrosis.</p>
Kambic	1992	<p>Urodynamics with filling pressures and bladder volumes measured before and after the operation at intervals of up to 36 months confirmed that adequate bladder capacity was achieved.</p> <p>There were no operative complications.</p> <p>Postmortem histological evaluations revealed a smooth epithelialized inner surface with no traces of any surface irregularities or suture lines.</p> <p>The biodegradable acetylated tissue provides an intact structural reservoir for urine and serves as a template for epithelial regeneration.</p>
Leungwattanakij	2000	<p>Pericardial graft group revealed a mild to moderate degree of fibrosis surrounding the patch at 4 months.</p> <p>The elastic fibers of the tunica albuginea around the graft material were oriented only in a circular direction.</p> <p>All the animals survived this procedure without any adverse complications.</p>
Portis	2000	<p>One control and one HPM animal developed uremia 5 and 7 days, respectively, and were euthanized. Examination showed a defect at the sutured bladder edges in control animal, while the HPM animal had a hole in the central portion of the placental membrane well away from the suture line.</p> <p>Postoperatively, urine infection was documented in 11 animals at 6 weeks follow-up (1 control, 3 porcine bowel ATM, 2 BP, 3 HPM, and 2 SIS), which was treated with antibiotics for 5 days.</p> <p>Detrusor leak point pressures significantly increased in PB animal after 6 weeks.</p> <p>Cystograms at 12 weeks showed the absence of reflux in all animals.</p> <p>The degree of adhesions between bladder and bowel among animals in BP was similar to the control group at 12 weeks; however, all BP grafts rejected at 12 weeks.</p> <p>Limited but superior histologic evidence of epithelialization was observed only with SIS.</p>

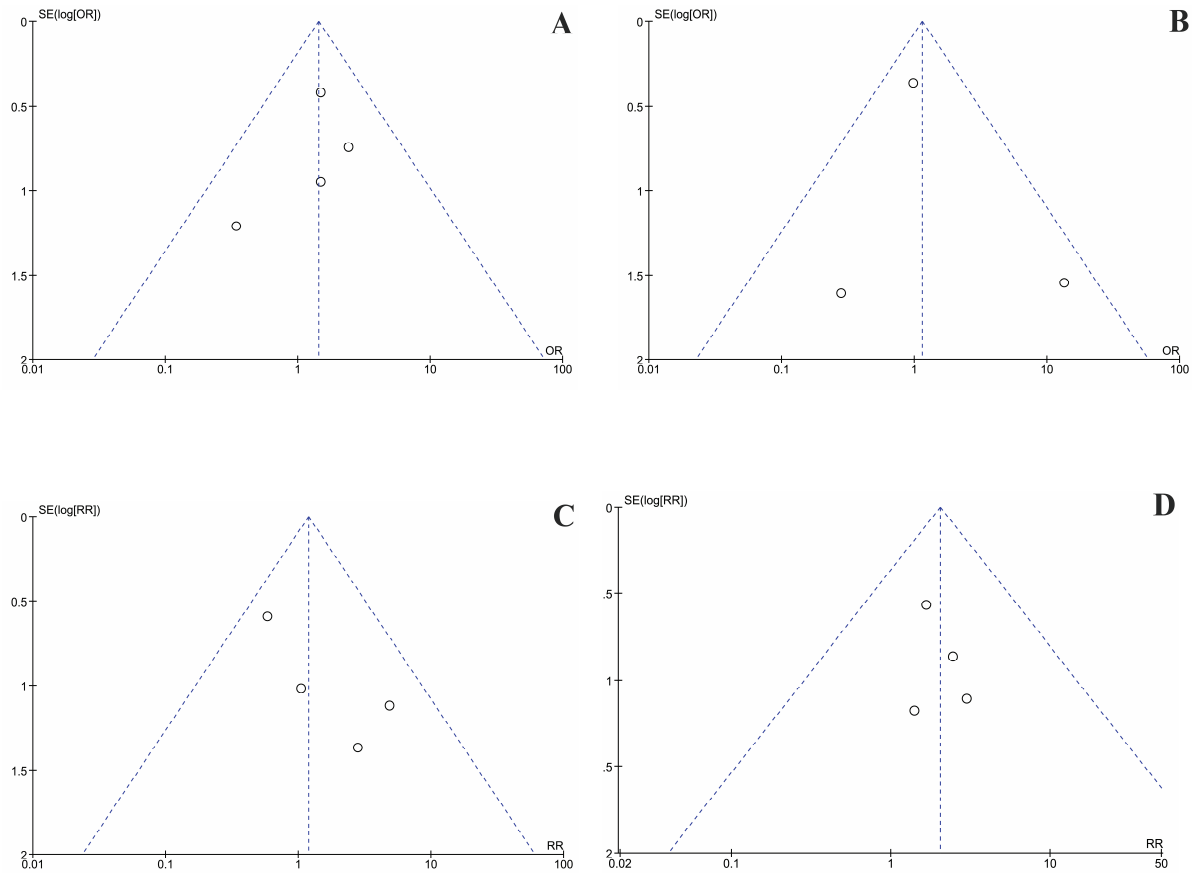
		BP was the least favorable and difficult to handle; however, the bladder of these animals was larger than one would have anticipated in the face of complete graft rejection.
Leungwattanakij	2003	<p>Four months after pericardial graft replacement, the penile tissue revealed moderate degrees of fibrosis as compared to the controls. The elastic fibers of the tunica albuginea around the graft material were oriented in only a circular direction.</p> <p>At 4 months, the vein graft group revealed minimal degree of fibrosis surrounding the patch. Mild foreign body reaction around the nylon suture material was present.</p> <p>Based on PCR amplification, the band density of TGF-1/-actin ratio was significantly higher in the pericardial graft group than that in the controls, but not significantly different from that of the vein graft group. However, the band density of TGF-1/-actin ratio in the vein graft group was similar to the control.</p> <p>Vein graft may be a more ideal substance to be used as the tunica albuginea substitute than the pericardial graft.</p>
Leungwattanakij	2003	<p>All the animals survived the procedure with no adverse complications.</p> <p>Foreign-body reaction around the Nylon suture at 4 and 6 months in all groups compared with the controls.</p> <p>Erectile function, assessed by cavernosal nerve stimulation, did not differ significantly in any of the groups.</p> <p>Minimal fibrosis surrounding the dermal and vein grafts and the tunica albuginea had elastic fibres which were orientated in two directions at 4 and 6 months.</p> <p>Moderate to severe fibrosis in the Gore-Tex graft at 4 and 6 months. In the pericardial graft there was a moderate fibrosis at 4 months with only minimal fibrosis at 6 months.</p>
Lara	2004	<p>Retrograde urethrograms showed that the urethral healing was complete in six animals, without stenosis, leakage, fistulas, or dilations associated with complete epithelization of urethras (20%). There was no evidence of a residual pericardial graft, active granulation, or calcification in any of the six animals studied.</p> <p>The remaining 24 animals (80%) presented with urethrocutaneous fistulas without stenosis. One of the animals died of a respiratory infection four months after the surgery, when a retrograde urethrogram was performed.</p>
Ayyildiz	2006	<p>Mortality and major complications were not observed up to 21 days.</p> <p>Urethrographic, macroscopic, and microscopic observations were used to generate a scoring system, including the absence of inflammation, fibrosis, necrosis, hyperemia, foreign material reaction, and fistula as well as the presence of neovascularization, intraluminal epithelial integrity, and extraluminal epithelial integrity. These parameters were used to evaluate the operation results at 21 days. Accordingly, the use of BP was associated with best success rate compared with primary repair and other grafts. The BP graft fulfilled all parameters except for fibrosis (i.e. 8 points).</p>
Mimura	2010	<p>At 8 weeks after augmentation, the bladder volume of the BP-augmented bladders was significantly larger than those at 1, 2, and 4 weeks. However, the compliances of the bladders did not change significantly. In addition, the compliance of BP-augmented bladders at 8 weeks was significantly higher than those at 1, 2 and 4 weeks.</p>
Kajbafzadeh	2011	<p>All rabbits survived and no post-surgical complications were found. Implanted tissues remained at the same place in the bladder wall and there was no significant reactive or infectious change in gross visualization of bladders.</p> <p>Histological evaluation showed no significant inflammatory change in comparison with normal tissue 4 weeks after grafting.</p> <p>The inflammation showed complete resolution by 8 weeks.</p> <p>Microscopic evaluation revealed variable degrees of regeneration in implanted tissues as a semi-organized muscular layer and new vessels in the margins of graft in autologous muscle fragment-seeded TEP, while there was a homogeneous pattern of SMCs and new vessels in both the margins and center of graft in autologous SMC-seeded TEP.</p>
Sandomirsky	2016	<p>No cases of material rejection, immunogenic inflammation, or postoperative period complications were detected up to 7 months follow-up.</p> <p>After 3 months the collagen structure of the graft was rearranged and mucous membrane epithelization appeared and 4 months after grafting, almost a complete xenopericardium</p>

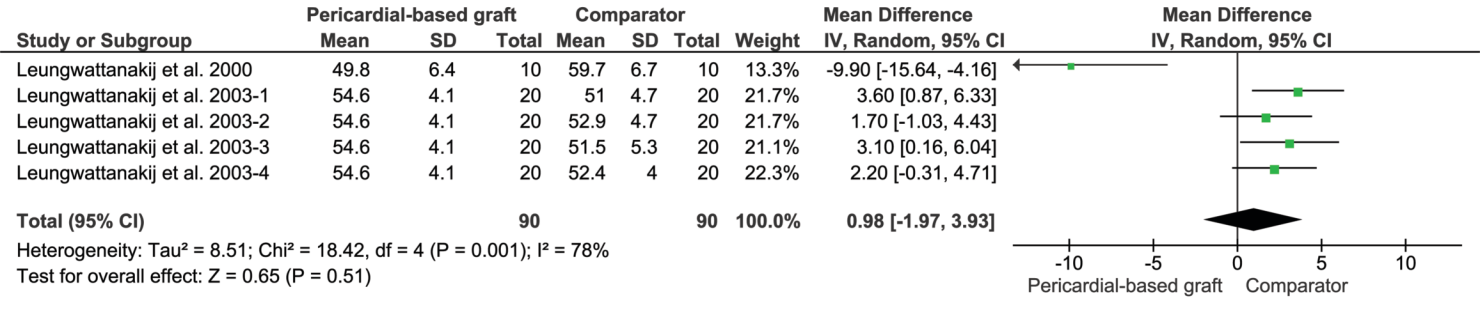
		<p>epithelialization took place.</p> <p>After 6 months the inner surface of the bladder wall consisted of normal mucosa, lined by fully formed epithelium.</p> <p>By the 7th month, transitional epithelium was normal. The muscle layer was largely restored. The graft retained its structural integrity and contained many functioning vessels. In the deeper layers, muscle tissue significantly invaded the pericardium from both sides, while in the surface layers myocytes formed gentle unidirectional chains between pericardial fibers.</p> <p>A year after implantation, the xenopericardium still retained its structural integrity and was surrounded with calm connective tissue.</p>
--	--	---

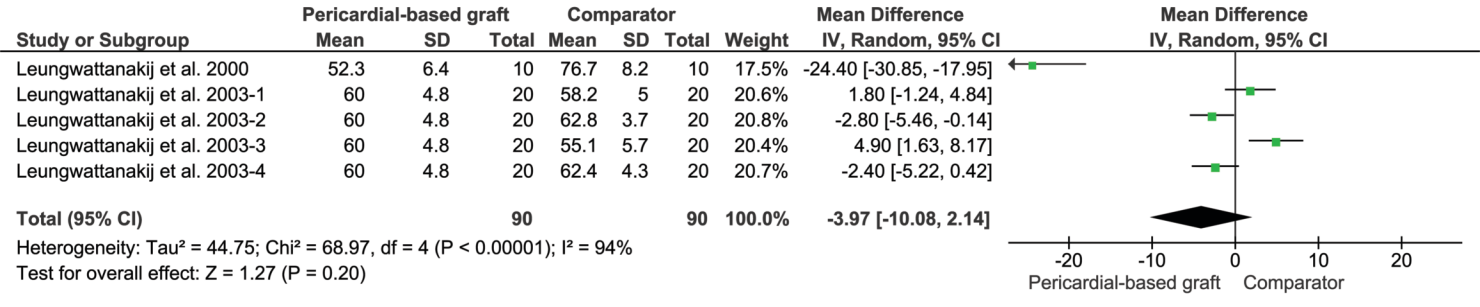
ATM, acellular tissue matrix; BP, bovine pericardium; HPM, human placental membranes; PCR, polymer chain reaction; SIS, small intestinal submucosa; SMC, smooth muscle cell; TEP, tissue-engineered pericardium



Supplementary Figure 2- Publication bias for studies comparing pericardial graft with comparators on (A) dissatisfaction rate, (B) glans hyposthesia, (C) penile shortening, and (D) penile curvature abnormalities in patients undergoing penile reconstructive surgeries







Supplementary Figure 4- Publication bias of pericardial graft versus comparators on (A) intracorporeal pressure at 5 V and (B) intracorporeal pressure at 7.5 V in animals undergoing penile reconstructive surgeries

