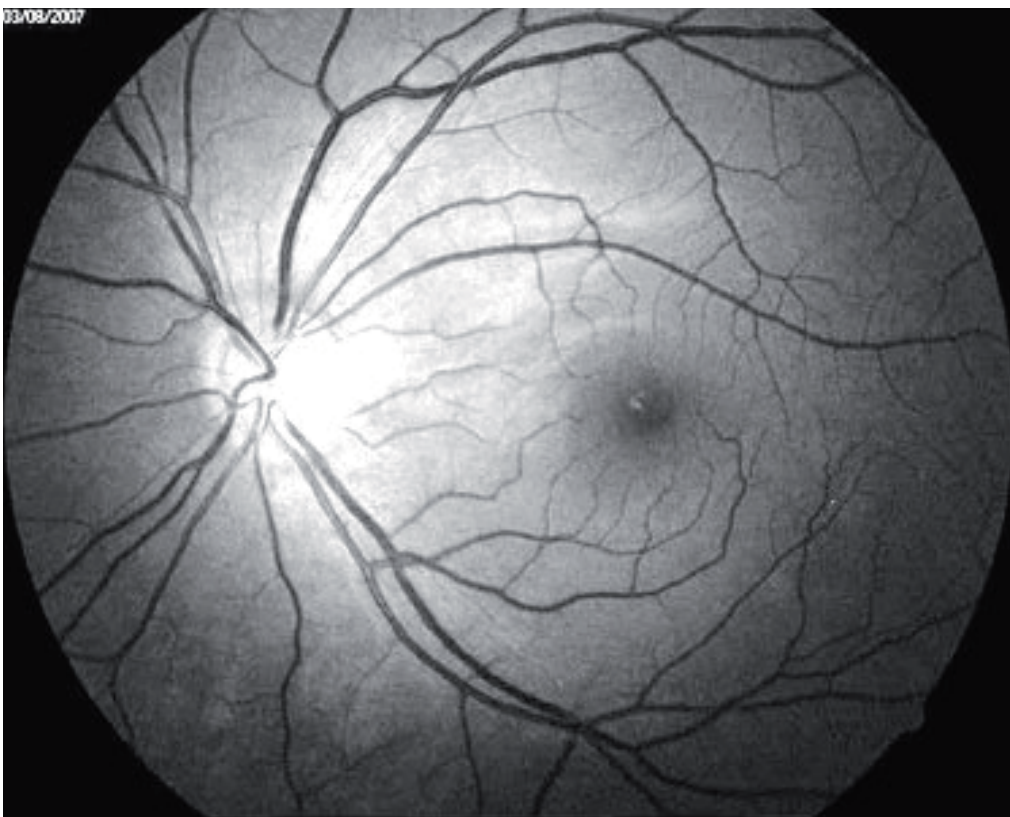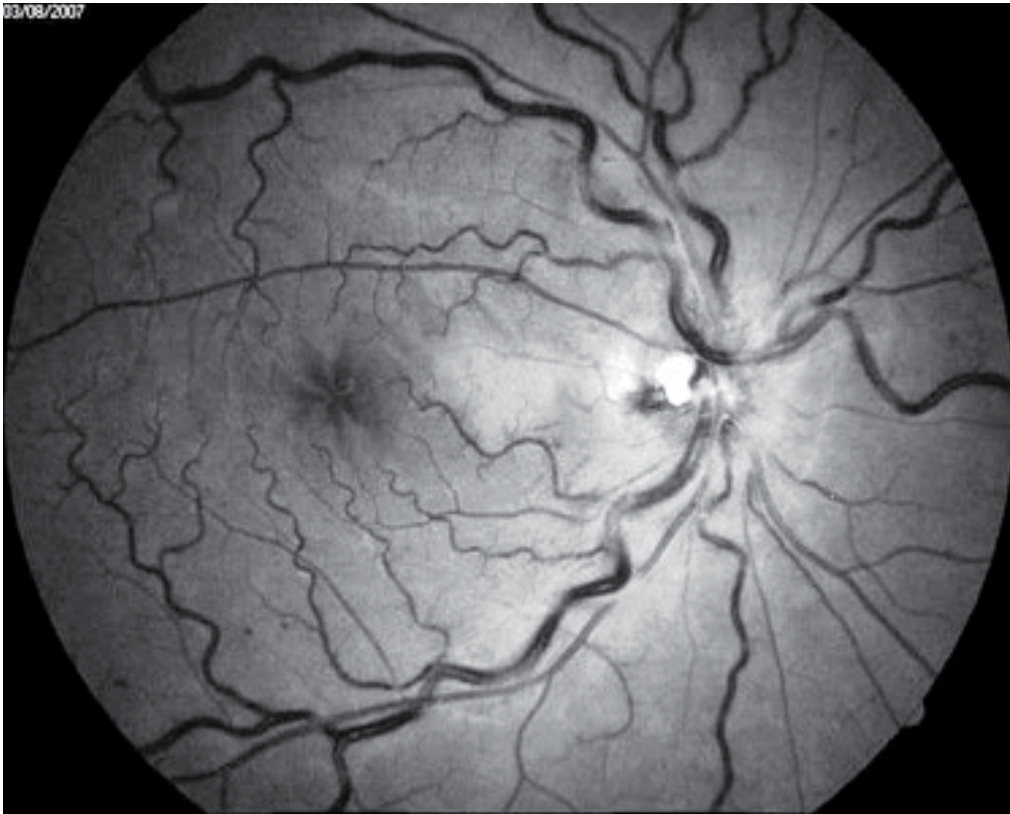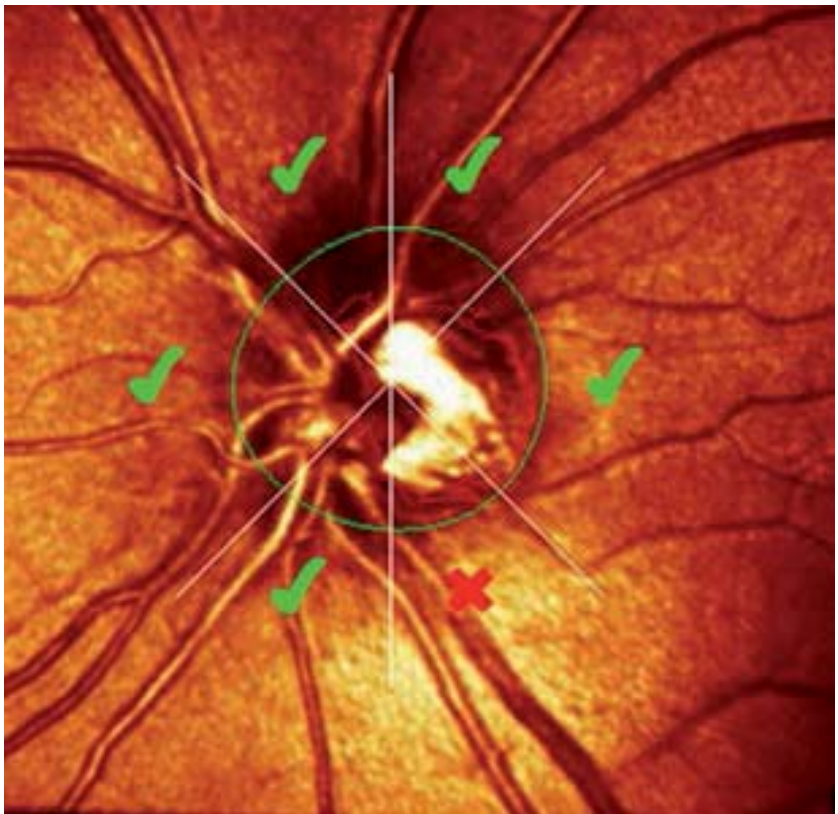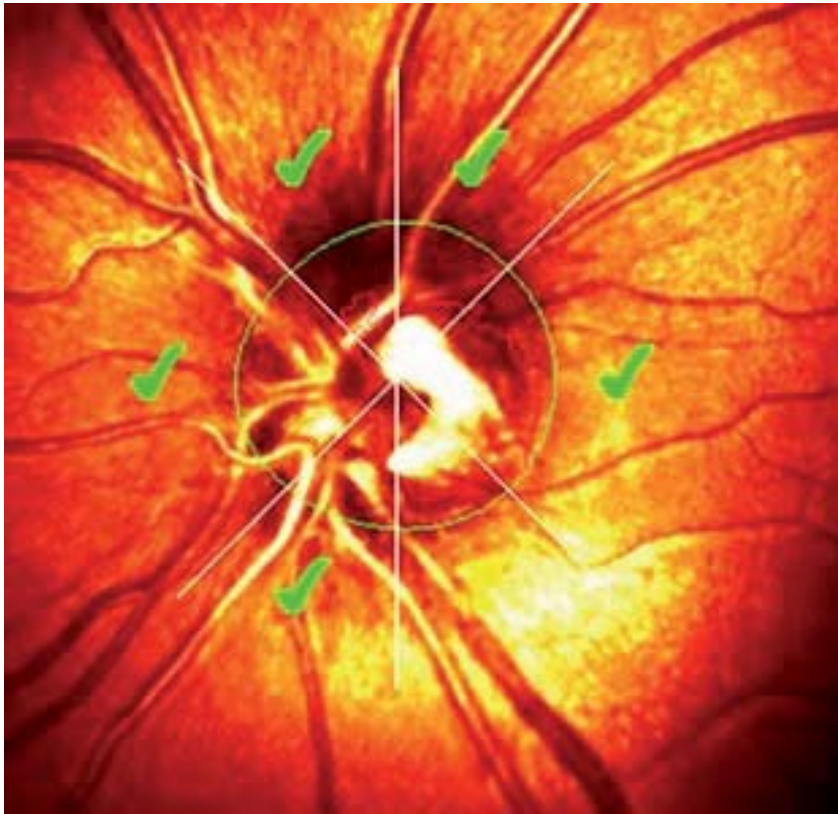




**Figure legend:**

Figure 1a: CRVO in the right eye (fundus fluorescein angiography).

Figure 1b: Fundus fluorescein angiography of the left eye.



**Figure legend:**

Figure 2a: Retinal tomography at the baseline (left eye).

Figure 2b: Retinal tomography after the 18 months of follow-up (left eye).